High Resolution Imaging and Anatomy

(Exploring the brain @ high-field MRI)

Noam Harel, Ph.D.
noam@cmrr.umn.edu

Center for Magnetic Resonance Research (CMRR)
Departments of Radiology & Neurosurgery
University of Minnesota Medical School

Signal-to-noise Ratio (SNR) & Spatial Resolution

8 x 8 x 8 mm^3 | 4 x 4 x 4 mm^3 | 2 x 2 x 2 mm^3 | 1 x 1 x 1 mm^3

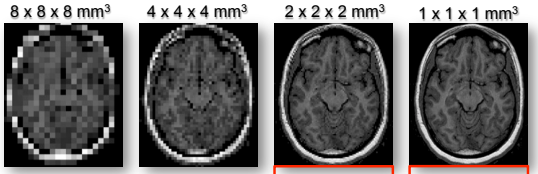

Voxel volume 2 mm^3 = 8

Voxel volume 1 mm^3 = 1

SNR is proportional to the imaged volume

higher magnetic field = SNR = higher spatial resolution

Benefits of high-field MRI

- Signal-to-noise ratio (SNR)
- Contrast (anatomical & functional)

Outline

- High-resolution vascular imaging
- High-resolution fMRI applications

- Anatomical contrast @ 7T MRI
- Clinical applications of @7T MRI

High Resolution Vascular Imaging
(Time-of-flight / inflow effects)

In a T_1-weighted sequence, long T_1 spins are saturated because they don't have time to recover

Arteries are bright due to unsaturated fresh blood fast inflow into slab

Veins are dark due to elevated concentration of deoxyhemoglobin (BOLD)

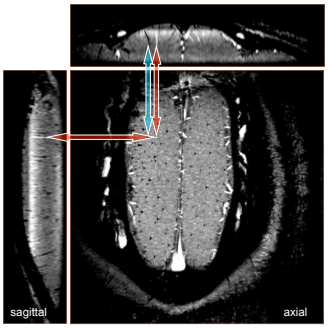

Cat, 9.4T

Bolan, Yacoub, Garwood, Ugurbil, Harel. *NeuroImage* 2006

High Resolution Vascular Imaging
(Time-of-flight / inflow effects)

In a T_1-weighted sequence, long T_1 spins are saturated because they don't have time to recover

Arteries are bright due to unsaturated fresh blood fast inflow into slab

Veins are dark due to elevated concentration of deoxyhemoglobin (BOLD)



Veins Arteries

Cat, 9.4T

Bolan, Yacoub, Garwood, Ugurbil, Harel. *NeuroImage* 2006

In-vivo High Resolution Vascular Imaging

Maximum Intensity Projections (MIP)

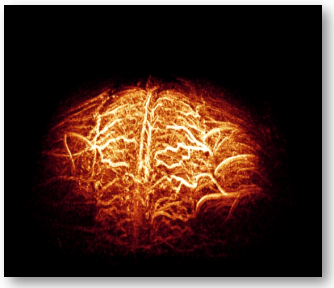

Cat, 9.4T

Bolan, Yacoub, Garwood, Ugurbil, Harel. *NeuroImage* 2006

High Resolution Vascular Imaging

(Time-of-flight / inflow effects)

3D Vessel Reconstruction

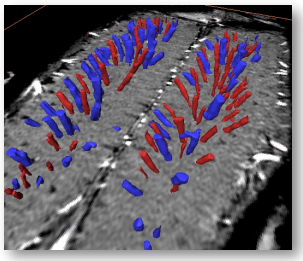

Vessel Classification

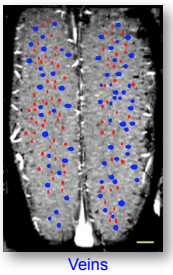

Veins
Arteries

Cat, 9.4T

Bolan, Yacoub, Garwood, Ugurbil, Harel. *NeuroImage* 2006

High Resolution Vascular Imaging

(SEM)

Ex-vivo

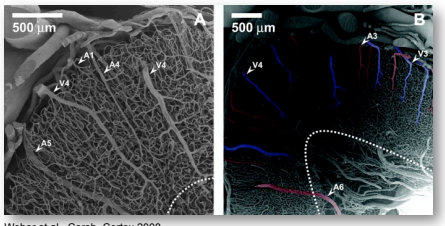

Weber et al., Cereb. Cortex 2008

Scanning electron micrographs of a vascular corrosion cast from monkey visual cortex (superior temporal gyrus)

BOLD signal and the underlying vascular system

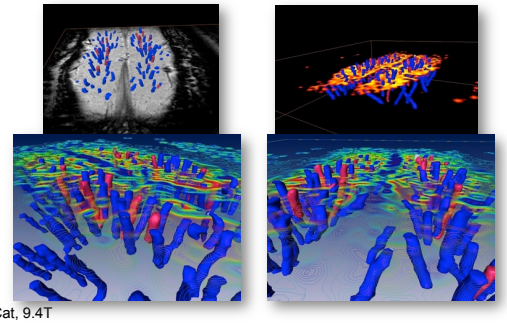

Cat, 9.4T
Multi slice BOLD fMRI:
Voxel size: 0.25 x 0.25 x 0.5 mm

Harel et al, *Front Neuroenergetics* 2010

High Resolution fMRI Applications

Anatomical Image

Functional Image

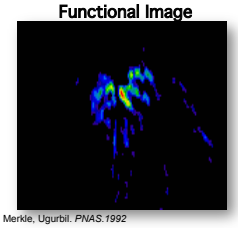

Ogawa, Tank, Menon, Ellermann, Kim, Merkle, Ugurbil. *PNAS.1992*

Advantages of high-field for fMRI

4 Tesla



7 Tesla



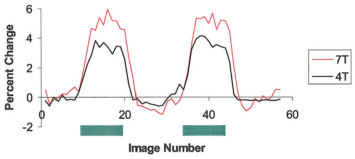

Yacoub, 2003

High Resolution fMRI Applications

Anatomical Image

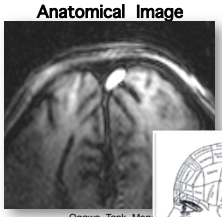

Functional Image

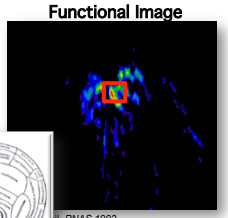

Ogawa, Tank, Men … *PNAS.1992*

Functional-units (… are believed to be the **basic c** … it in the brain

Brain Function and Localization

Functional Domains in Visual Cortex - Ocular Dominance Columns -

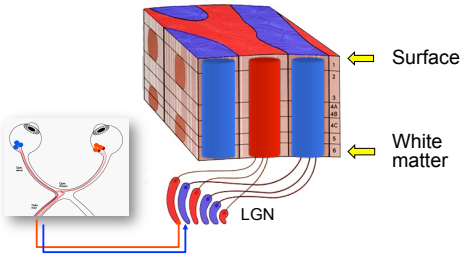

Neurons with similar response properties tend to cluster together in 'columns' extending through the entire cortex

Functional Domains in Visual Cortex - Ocular Dominance Columns -

Optical Imaging - Monkey

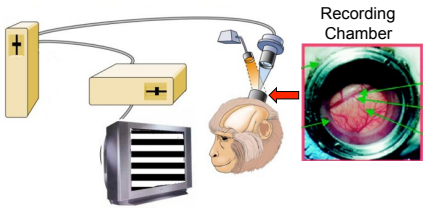

Functional Domains in Visual Cortex
- Ocular Dominance Columns -

Optical Imaging - Monkey

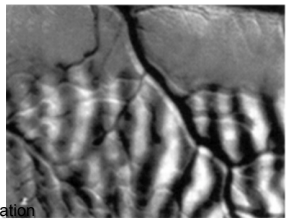

Monocular stimulation

Ts'o et al., 1990

Columns Mapping in Humans V1
Ocular Dominance Columns (ODC)

Anatomical (post-mortem)

Horton & Hedley-Whyte, 1984; Horton, 2006

ODC Spatial Organization

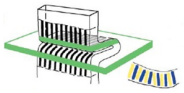

Cheng et al., 2001

Functional (fMRI)



Menon et al., 1997

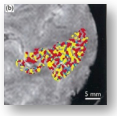

Dechent & Frahm, 2000

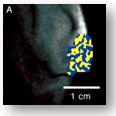

Goodyear & Menon, 2001

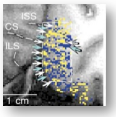

Cheng et al., 2001

Columns Mapping in Humans V1
Ocular Dominance Columns (ODC)

SE-BOLD 7 T

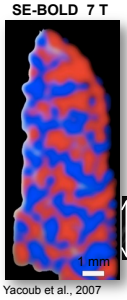

Yacoub et al., 2007

Monocular stimulation

ODC Spatial Organization

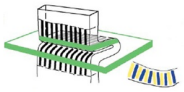

Cheng et al., 2001

EPI Image

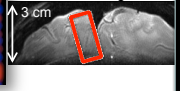

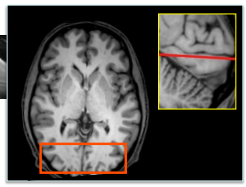

Image resolution: 0.5 x 0.5 x 3 mm

Functional Domains in Visual Cortex
- Orientation Columns -

Electrophysiological Recording

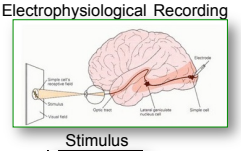

Stimulus

[redacted]del

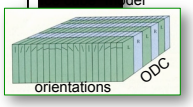

Cell Discharge



Hubel & Wiesel, 1968

Functional Domains in Visual Cortex
- Orientation Columns -

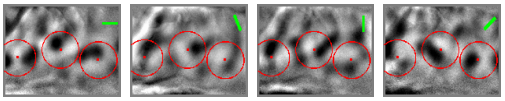



Hubel & Wiesel, 1968

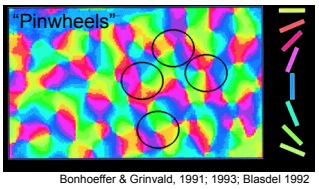

Bonhoeffer & Grinvald, 1991; 1993; Blasdel 1992

Orientation selective regions in Human V1

Phase Map - fMRI



Orientation selective regions in Human V1

Phase Map - fMRI

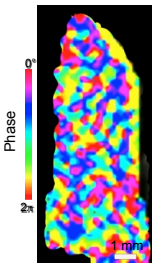

Orientation Map – Optical Imaging



Bonhoeffer & Grinvald, 1991; 1993

Does the fMRI-Phase Map Reveal Orientation Specific Activation Zones?

Spatial Relationships Between Ocular Dominance and Orientation Columns

1. Radial arrangement of orientation columns (***pinwheels***)
2. Pinwheels rotate in ***opposite*** directions
3. Pinwheels ***centers*** (singularities) tend to concentrated in the ***center*** of ocular dominance columns
4. Iso-orientation lines intersect the borders between ocular dominance borders at ***right angles*** (***linear zones***)

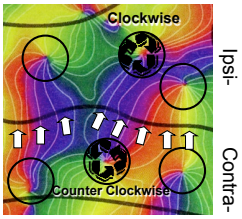

Optical Imaging - monkey

Blasdel, JNS 1992
Bartfeld & Grinvald, PNAS 1992
Obermayer & Blasdel, JNS 1993
Crair et al., J Neurophysiol. 1997
Hubener et al., JNS 1997

Orientation Columns – Human fMRI (pinwheel)

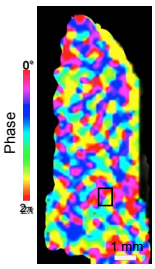

fMRI - human



Optical Imaging - cat

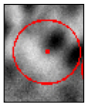

Yacoub, Harel & Ugurbil, *PNAS* 2008

ODC & Phase maps in human V1

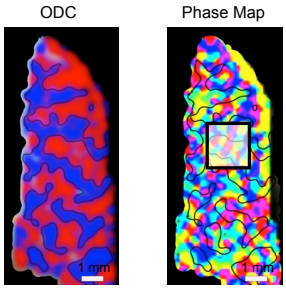

Ocular Dominance & Orientation Columns in Human V1

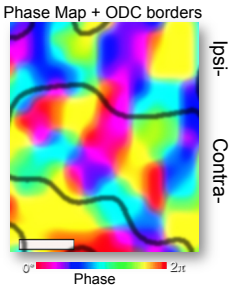

Scalebar = 0.5 mm

Yacoub, Harel & Ugurbil, *PNAS* 2008

1. Radial (pinwheel) arrangement

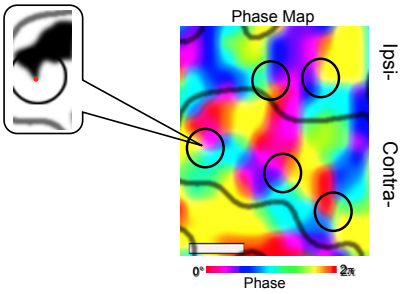

Scalebar = 0.5 mm

Yacoub, Harel & Ugurbil, *PNAS* 2008

2. Clockwise & Counter Clockwise directions

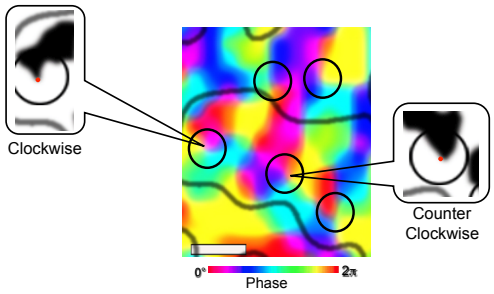

Scalebar = 0.5 mm

Yacoub, Harel & Ugurbil, *PNAS* 2008

3. Pinwheels centered in ODCs

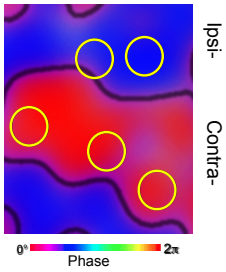

Scalebar = 0.5 mm

Yacoub, Harel & Ugurbil, *PNAS* 2008

4. Linear zones

Orientation preference changes along straight axes orthogonal to ODCs

Phase Map

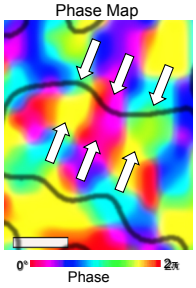

Scalebar = 0.5 mm

Yacoub, Harel & Ugurbil, *PNAS* 2008

Orientation Columns in Primary Visual Cortex

Human
fMRI (SE, 7T)



Yacoub, Harel & Ugurbil, *PNAS* 2008

Monkey
Optical Imaging

Obermayer & Blasdel, JNS 1993

Anatomical Imaging at Ultra-high Field MRI

Benefits of high-field (7 Tesla) MRI

1.5 T (clinical)

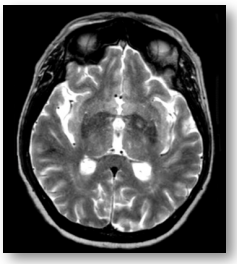

7 T

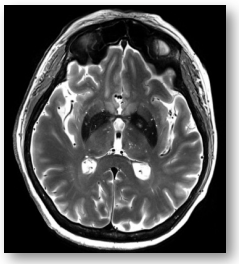

Noam Harel, University of Minnesota / CMRR

Benefits of High-field MRI

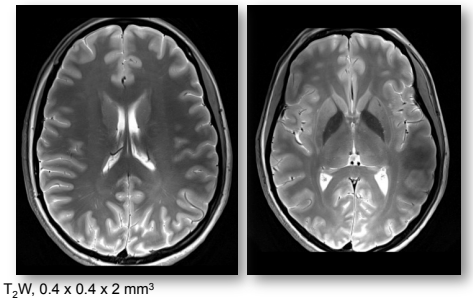

7T, T_2W, 0.4 x 0.4 x 2 mm^3

Noam Harel, University of Minnesota / CMRR

Susceptibility-Weighted Imaging (SWI)

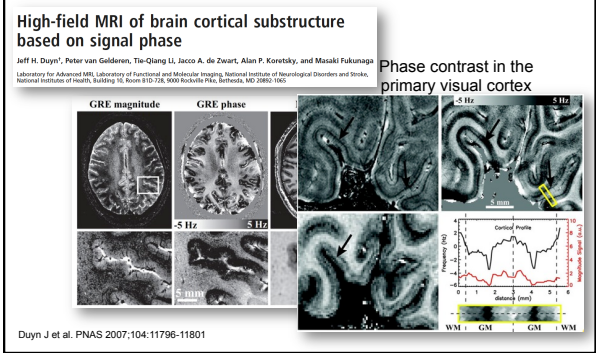

Phase contrast in the primary visual cortex

Duyn J et al. PNAS 2007;104:11796-11801

Anatomical contrast @ 7T

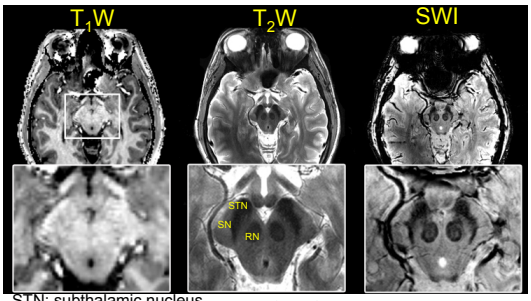

STN: subthalamic nucleus
SN: substantia nigra
RN: red nucleus

SWI: Susceptibility-weighted imaging

Abosch, Yacoub, Ugurbil, Harel. *2010*

Susceptibility-Weighted Imaging @ 7T

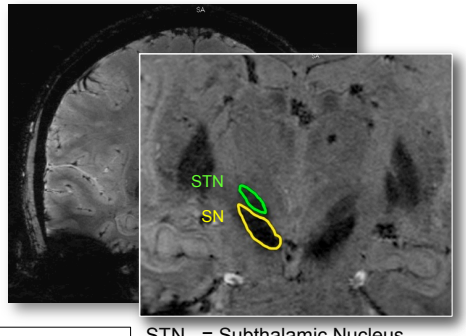

Magnet: 7T
Resolution: 0.4 x 0.4 x 0.8 mm

STN = Subthalamic Nucleus
SN = Substantia Nigra

Susceptibility-Weighted Imaging @ 7T

Schaltenbrand and Wahren Atlas (*Ex-vivo*)

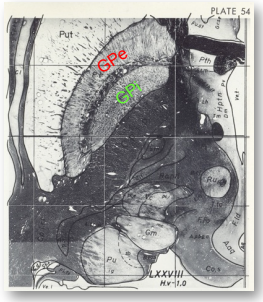

SWI @ 7T (*In-vivo*)

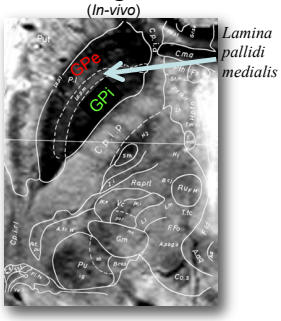

GP = Globus pallidus

Abosch, Yacoub, Ugurbil, Harel. *2010*

Thalamus level

Atlas (*Ex-vivo*)

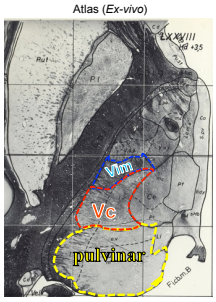

SWI @ 7T (*In-vivo*)

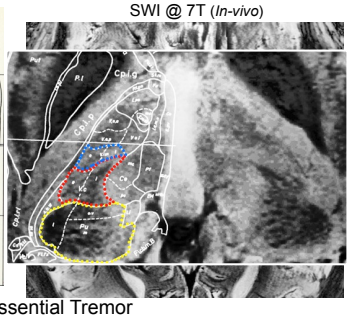

Vim = DBS Target for Essential Tremor
Vim = Ventralis intermedius (motor thalamus)
Vc = Ventral caudalis

Abosch, Yacoub, Ugurbil, Harel. *2010*

Detections of Brain Structures with 7 Tesla MRI

Patient-Specific Anatomical Model

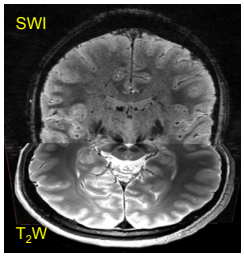

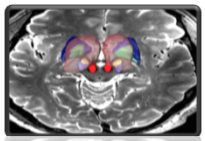

- Thalamus (Tha)
- Subthalamic nucleus (STN)
- Substantia nigra (SN)
- Red nucleus (RN)
- Globus Pallidus
  - GPi
  - GPe

Diffusion Weighted Imaging

Tractography (DTI / HARDI)

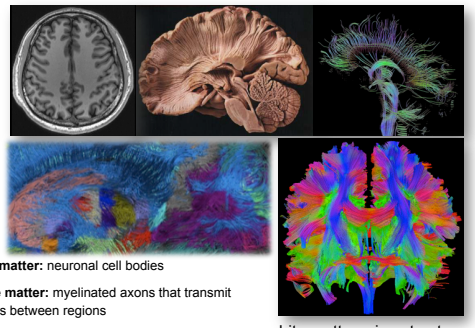

Gray matter: neuronal cell bodies

White matter: myelinated axons that transmit signals between regions

white matter microstructures

Tractography

(diffusion-weighted imaging - HARDI)

Nigrostriatal tract

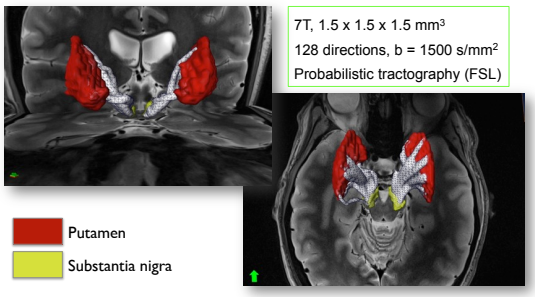

7T, 1.5 x 1.5 x 1.5 mm^3
128 directions, b = 1500 s/mm^2
Probabilistic tractography (FSL)

- Putamen
- Substantia nigra

Lenglet, Abosch, Yacoub, De Martino, Sapiro, Harel. *PLoS ONE 2012*

Tractography

Basal Ganglia and Thalamus

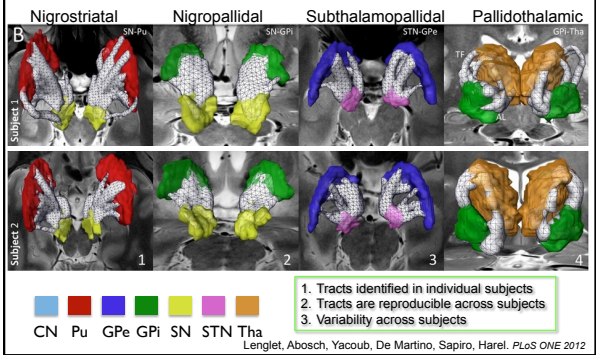

1. Tracts identified in individual subjects
2. Tracts are reproducible across subjects
3. Variability across subjects

Lenglet, Abosch, Yacoub, De Martino, Sapiro, Harel. *PLoS ONE 2012*

Clinical applications of high-resolution 7T MRI

Clinical applications of high-resolution 7T MRI

Direct Visualization of Parkinson's Disease by In Vivo Human Brain Imaging Using 7.0T Magnetic Resonance Imaging

Zang-Hee Cho, PhD,[1*] Se-Hong Oh, MS,[1] Jong-Min Kim, MD, PhD,[2] Sung-Yeon Park, MS,[1] Dae-Hyuk Kwon, MS,[1] Hye-Jin Jeong, BS,[1] Young-Bo Kim, MD, PhD,[1] Je-Geun Chi, MD, PhD,[1,3] Chan-Woong Park, MD,[1] John Huston III, MD,[4] Kendall H. Lee, MD, PhD,[5] and Beom S. Jeon, MD, PhD[2]

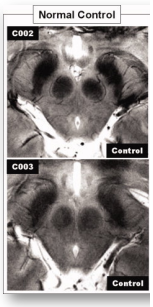

Movement Disorders
Volume 26, Issue 4, pages 713-718, 21 JAN 2011

Clinical applications of high-resolution 7T MRI

Direct Visualization of Parkinson's Disease by In Vivo Human Brain Imaging Using 7.0T Magnetic Resonance Imaging

Zang-Hee Cho, PhD,[1*] Se-Hong Oh, MS,[1] Jong-Min Kim, MD, PhD,[2] Sung-Yeon Park, MS,[1] Dae-Hyuk Kwon, MS,[1] Hye-Jin Jeong, BS,[1] Young-Bo Kim, MD, PhD,[1] Je-Geun Chi, MD, PhD,[1,3] Chan-Woong Park, MD,[1] John Huston III, MD,[4] Kendall H. Lee, MD, PhD,[5] and Beom S. Jeon, MD, PhD[2]

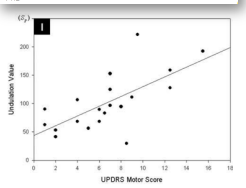

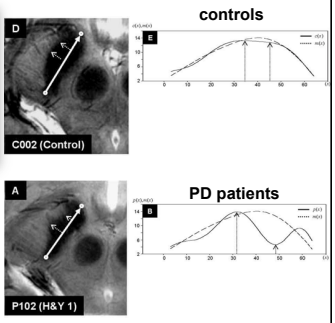

Movement Disorders
Volume 26, Issue 4, pages 713-718, 21 JAN 2011

What is Deep Brain Stimulation (DBS)?

- A surgically implanted medical device - "brain pacemaker"
- Sends electrical impulses to the brain

FDA approved DBS applications:

Movement disorders, including:

- Parkinson's disease
- Essential tremor

Humanitarian Device Exemption (HDE):

- Obsessive-Compulsive Disorder (OCD)
- Major Depression
- Epilepsy
- Dystonia

Under clinical trials:

- Alzheimer's disease
- Tourette's Syndrome

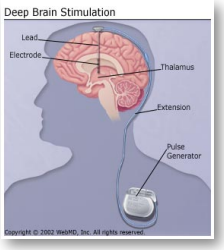

Over 120,000 DBS cases worldwide

DBS = Deep Brain Stimulation

DBS Surgery Today

Limitation of Current Procedure

2D - Stereotactic atlas

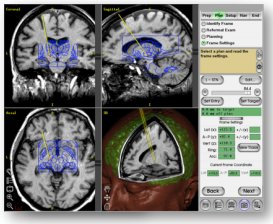

Microelectrode recording (*MER*)

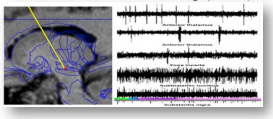

Patient awake during surgery

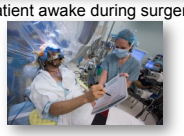

Consensus Coordinates (STN):		**Range**
• Lateral	12 mm	(8.7 mm – 14.5 mm)
• Posterior to MCP	4 mm	(3.5 mm posterior to 0.5 mm anterior)
• Below MCP	5 mm	(1.3 mm – 6 mm)

Success of DBS surgery is critically dependent on the precise placement of the electrodes into the target structures

Can 7T images be used for DBS targeting?

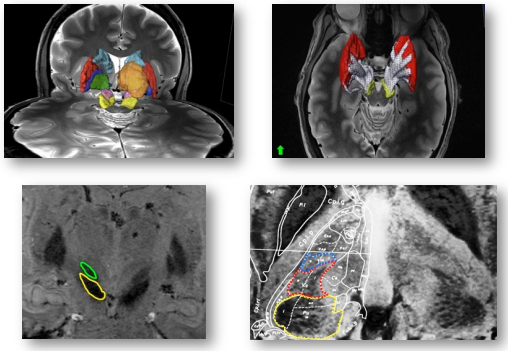

7T-MRI for Clinical Surgical Targeting

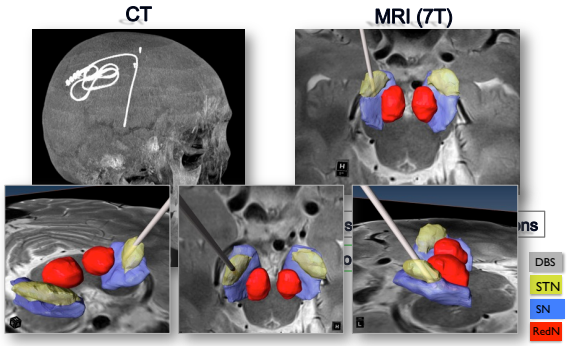

Noam Harel – U of Minnesota / CMRR

Post-Surgery DBS: active contacts

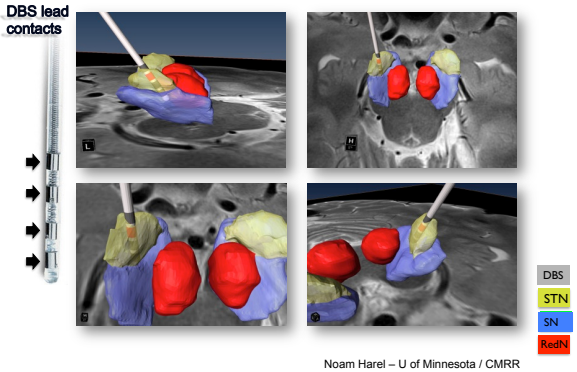

Noam Harel – U of Minnesota / CMRR

Acknowledgements



U of Minnesota / CMRR

Essa Yacoub
Patrick Bolan
Steen Moeller
Christophe Lenglet
Yuval Duchin
Kamil Ugurbil

Duke University

Guillermo Sapiro

Neurosurgery

Aviva Abosch
Jon McIver

Neurology

Jerrold Vitek

HUMAN Connectome PROJECT

Work supported in part by the National Institutes of Health (R01NS085188, P41RR08079, P30 NS057091, R01 NS081118) the W.M. Keck Foundation, and MIND institute.